

## GENERAL GYNECOLOGY

# Creation of a neovagina by Davydov's laparoscopic modified technique in patients with Rokitansky syndrome

Luigi Fedele, MD; Giada Frontino, MD; Elisa Restelli, MD; Nevio Ciappina, MD; Francesca Motta, MD; Stefano Bianchi, MD

**OBJECTIVE:** The purpose of this study was to assess anatomic and functional results after the laparoscopic Davydov procedure for the creation of a neovagina in Rokitansky syndrome.

**STUDY DESIGN:** Thirty patients with Rokitansky syndrome underwent the laparoscopic Davydov technique from June 2005–August 2008. Mean follow-up time lasted 30 months (range, 6–44 months) and included clinical examinations and evaluation of the quality of sexual intercourse; vaginostomy, Schiller's test, and neovaginal biopsies were performed after 6 and 12 months. Functional results were assessed with the use of Rosen's Female Sexual Function Index and were compared with age-matched normal control subjects.

**RESULTS:** No perioperative complications occurred. At 6 months, anatomic success was achieved in 97% of the patients ( $n = 29$ ); functional success and optimal results for the Female Sexual Function Index questionnaire were obtained in 96% of patients. Vaginostomy and biopsy results showed a normal iodine-positive vaginal epithelium.

**CONCLUSION:** The Davydov technique seems to be a safe and effective treatment for vaginal agenesis in patients with Rokitansky syndrome.

**Key words:** Davydov technique, laparoscopy, neovagina, Rokitansky syndrome, sexual function

Cite this article as: Fedele L, Frontino G, Restelli E, et al. Creation of a neovagina by Davydov's laparoscopic modified technique in patients with Rokitansky syndrome. *Am J Obstet Gynecol* 2010;202:33.e1-6.

The Mayer-Rokitansky-Kuster-Hauser syndrome is a malformation complex that is defined by the absence of the vagina and uterus. Such condition is represented by primary amenorrhea, with a normal ovarian function, normal female karyotype, and secondary sexual characteristics. Anomalies of the urinary tract and the skeletal system are associated variably with the Rokitansky syndrome.<sup>1,2</sup> The exact inci-

dence of this syndrome is unknown, although the only recent epidemiologic study estimated it to be of 1:1500 to 1:4000 born female infants.<sup>3</sup> Numerous surgical and nonsurgical procedures have been described, all of which have aimed at creating a neovagina of adequate size and physiologic condition to permit normal sexual intercourse.<sup>4</sup>

The purpose of this study was to assess anatomic, functional, and sexual long-term outcomes after the creation of a neovagina with Davydov's laparoscopically modified technique, in which the vesicorectal space is coated by peritoneum.<sup>5-10</sup>

## MATERIALS AND METHODS

The subjects of the study were all patients ( $n = 30$ ) with Rokitansky syndrome who underwent surgery by the same operator (L.F.), who used the laparoscopically modified Davydov technique from June 2005–August 2008 in a tertiary referral center for the Rokitansky syndrome at the University of Milan, Italy.

The preliminary hypothesis of our study was that the modified laparoscopically directed version of the Davydov procedure allows satisfactory anatomic and functional results for the creation of a neovagina in patients with Rokitansky syndrome.

Before surgery, all patients underwent pelvic and abdominal ultrasonography, pelvic magnetic resonance imaging, and karyotyping. Diagnostic criteria for Rokitansky syndrome were primary amenorrhea, vaginal agenesis, absence of the uterus, normal external genitalia, and a normal female karyotype (46,XX). The presence of a pelvic kidney was considered a contraindication to Davydov's procedure.

The modified laparoscopic Davydov technique involves a laparoscopic step, followed by a vaginal approach. During the laparoscopic step, after exploration of the pelvis and abdominal cavity, the strand that connects the 2 rudimentary uterine horns is lifted, and the peritoneum immediately below is incised transversely for a section of 4–5 cm (Figure 1). Guided by the middle finger, which is inserted in the patient's rectum, this incision is extended in a horseshoe-shaped fashion for approximately 1 cm into the connective tissue beneath which separates the bladder from the rectum. In order to mobilize the peritoneum, which will constitute the neovaginal walls and vault, the round ligaments are identified by applying traction on the uterine remnants and then are cut bilaterally. The supravaginal peritoneum is

From the Department of Obstetrics and Gynecology, Fondazione "Policlinico-Mangiagalli-Regina Elena" (Drs Fedele, Frontino, Restelli, Ciappina, and Motta), and the Department of Obstetrics and Gynecology, Ospedale San Giuseppe (Dr Bianchi), University of Milan, Milan, Italy.

Received April 22, 2009; revised June 16, 2009; accepted Aug. 19, 2009.

Reprints: Luigi Fedele, MD, Clinica Ostetrica e Ginecologica I, Università di Milano, Istituto Luigi Mangiagalli, Via della Commenda 12, 20122 Milan, Italy. [luigi.fedele@unimi.it](mailto:luigi.fedele@unimi.it).

Authorship and contribution to the article are limited to the 6 authors indicated. There was no outside funding or technical assistance with the production of this article.

0002-9378/\$36.00

© 2010 Mosby, Inc. All rights reserved.

doi: 10.1016/j.ajog.2009.08.035

FIGURE 1

### The modified laparoscopic Davydov technique involves a laparoscopic step

The strand that connects the 2 rudimental uterine horns is lifted, and the peritoneum immediately below is incised transversely for a section of 4–5 cm (dotted line).

Fedele. Creation of neovagina in patients with Rokitansky syndrome. *Am J Obstet Gynecol* 2010.

incised along the apparent line that connects the rudiments. A monofilament (polydioxanone synthetic absorbable suture [PDS] 2-0) is used to create 2 purse-string sutures for each hemi pelvis. Each suture is begun from the mobilized peritoneum above the bladder dome by transfixing consecutively the round ligament, the tubal isthmus, the uteroovarian ligament, and the lateral peritoneal leaf, prior identification of the ureters. The 2 sutures then include the lateral aspect of the mesorectum and the end including the anterior aspect of the rectal serosa immediately below the rectosigmoid junction (Figure 2). The perineal step allows the creation of an anastomosis between the previously incised pelvic peritoneum and the mucosa of the vaginal vestibulum. An H-shaped incision is made on the vaginal vestibulum, with a transverse cut from the base of 1 minor labia to the contralateral and 2 vertical cuts that run adjacent to the extremities of the transverse incision (Figure 3). The dissection between the bladder and rectum is started along the vertical incisions, which creates 2 paramedian tunnels, while the median raphe is cut subsequently. The surgeon works by blunt and sharp dissection until the peritoneal margins of the laparoscopically performed transverse incision are iden-

tified. The peritoneal margins are then hooked by interrupted sutures in PDS 3-0 to the vestibulum's mucosa, which start from the median line where mobilization of the margins is easiest (Figures 4 and 5). At this point, a paraffin gauze dressing tampon can be inserted in the peritoneum-coated neovagina.

Removal of the catheter and gauze dressing and the use of vaginal obturators were scheduled 48 hours after surgery. The obturators are made of soft latex and are 10 cm in length and 2.5 cm in width. Before use, the obturators are washed and sterilized with an antiseptic solution or otherwise simply washed and covered with a condom. An estrogen-based vaginal cream is applied to the obturators before use to promote neovaginal epithelization. All patients have to use the obturators for approximately 6–8 hours each day and perform neovaginal irrigations with sterile saline solution daily.

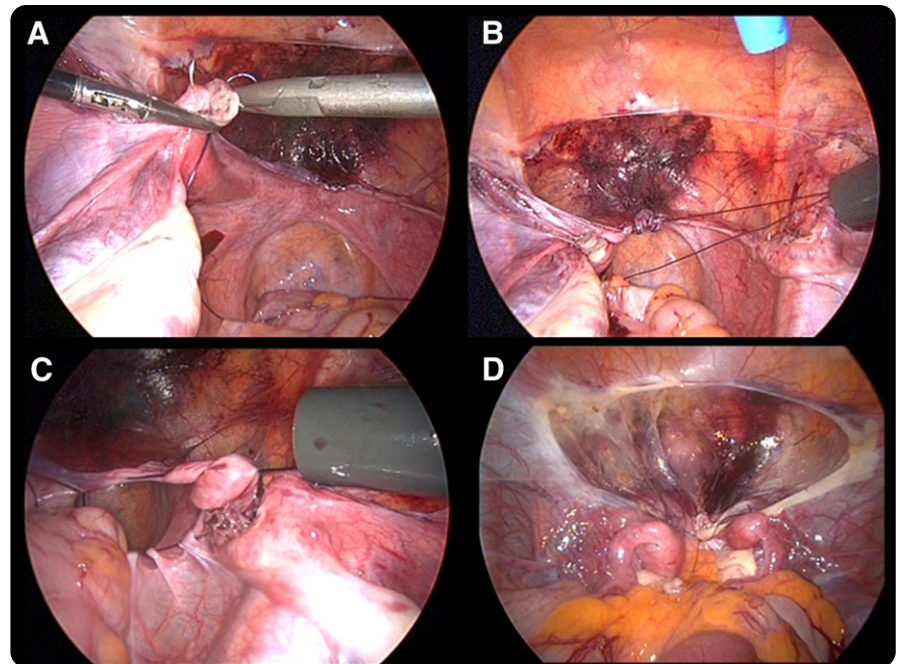
Clinical follow-up was planned at 1, 3, 6, and 12 months after surgery and every

year thereafter. At each follow-up visit, vaginal and rectal examinations and evaluation of symptoms and of the quality of sexual intercourse were performed. Vaginoscopy was performed at 6 months and 1 year after surgery, along with a biopsy and Schiller's test to evaluate epithelization of the neovagina.

At the first follow-up visit, the frequency in use of obturators was reassessed, and the possibility to start sexual activity was evaluated based on the anatomic results. Primary outcomes were the achievement of anatomic and functional success. *Anatomic success* was defined, as previously reported,<sup>11</sup> as a neovagina of  $\geq 6$  cm in length that allows the easy introduction of 2 fingers within 6 months after surgery. Achievement of functional success was considered when the patient reported satisfactory sexual intercourse that started from 6 months after surgery. Functional results were also assessed by the use of a standardized questionnaire, the Female Sexual Function Index (FSFI),<sup>12</sup> which is an interna-

FIGURE 2

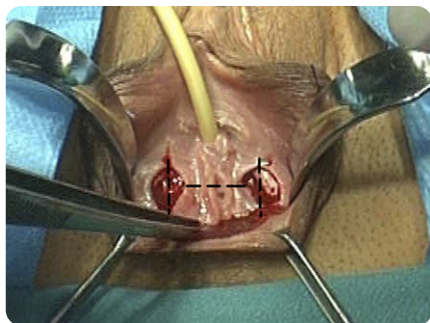
### Creation of 2 purse-string sutures for each hemi pelvis



A, Transfixion of the round ligament; B, creation of the left purse-string suture by transfixing consecutively the round ligament, the tubal isthmus, the uteroovarian ligament, the lateral peritoneal leaf, and the rectal serosa; C, closure of the right purse-string; D, final laparoscopic vision.

Fedele. Creation of neovagina in patients with Rokitansky syndrome. *Am J Obstet Gynecol* 2010.

**FIGURE 3**  
Perineal step



An H-shaped incision is made on the vaginal vestibulum (dashed line).

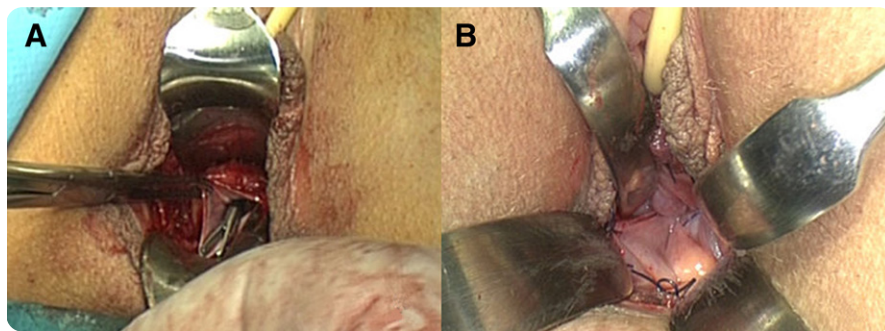
Fedele. Creation of neovagina in patients with Rokitansky syndrome. *Am J Obstet Gynecol* 2010.

tionally validated test for the evaluation of female quality of sexual function. FSFI assesses 6 domains: desire, arousal, lubrication, orgasm, satisfaction, and pain. The functional result is considered to be “very good” when the FSFI score is  $>30$ , “good” when the score is between 23–29, and “poor” when the score is  $<23$ . The highest total FSFI score that may be obtained is 36. Patients who had started sexual activity completed the questionnaire 6 months after surgery. The results that were obtained were compared with age-matched normal control subjects. The results of the FSFI questionnaire were analyzed with STATA software (Stata Corp, College Station, TX). The mean score ( $\pm$  SD) and 95% confidence interval for each item were calculated, and the comparison between cases and normal age-matched control subjects was done with the  $t$  test. A probability value of  $< .05$  was considered statistically significant.

## RESULTS

The mean age of patients at surgery was  $20 \pm 4.3$  years (range, 15–34 years). None of the patients had had previous pelvic surgeries. The procedure was also performed in 2 patients with a single kidney; we excluded from our study 2 patients with pelvic kidney who underwent the Vecchietti technique.<sup>13,14</sup> The mean length of the vaginal fovea before surgery was 9.4 mm (range, 5–25 mm). In all cases, a median uterine structure was ab-

**FIGURE 4**



**A**, The pelvic peritoneum is identified before the creation of an anastomosis with the vaginal vestibulum; **B**, final vision of the neovagina, which is covered by peritoneum.

Fedele. Creation of neovagina in patients with Rokitansky syndrome. *Am J Obstet Gynecol* 2010.

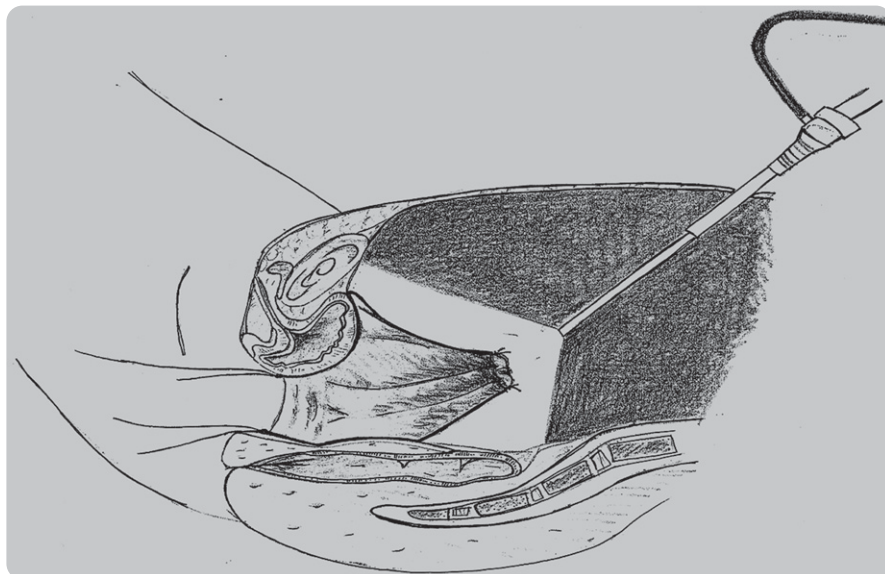
sent; uterine remnants were present in all patients, which were unilateral in 4 cases (13%) and bilateral in 26 cases (87%). The mean diameter of the remnants was 22 mm. Only 1 patient had a single ovary; in 6 patients (20.7%), the ovaries were extrapelvic.

The surgical procedure was completed successfully in all patients. The operating time was  $125 \pm 23$  minutes, and the intraoperative bleeding was  $178 \pm 139$  mL. No perioperative complications occurred. The catheter was removed  $2.45 \pm 1.1$  days after surgery. Five cases of uri-

nary retention were observed after catheter removal, which resolved after the catheter was repositioned for 4 days and antibiotic treatment. In 1 case at ultrasound examination, a hematoma of 4 cm diameter that eventually resolved spontaneously was observed on the rectum's anterior wall. The patients were dismissed from the hospital at a mean of  $3.9 \pm 1.4$  days after surgery.

At the end of the surgical procedure, the neovagina that was obtained was approximately 7–8 cm in depth and 3 cm in width. At hospital dismissal, the mean

**FIGURE 5**



Final view after creation of the vaginal vault and the anastomosis between the peritoneum and vestibulum.

Fedele. Creation of neovagina in patients with Rokitansky syndrome. *Am J Obstet Gynecol* 2010.

**TABLE**  
**Case vs control FSFI scores**

Variable	Cases	Control subjects
Total Female Sexual Function Index score <sup>a</sup>	28 ± 4.6 (26.9–30.0) <sup>b</sup>	31 ± 2.25 (30.0–32.0)
≥30, n	8	17
24–29, n	15	7
≤23, n	1	0
Desire <sup>a</sup>	4.3 ± 0.9 (3.9–4.6) <sup>c</sup>	4.8 ± 0.7 (4.5–5.1)
Arousal <sup>a</sup>	4.8 ± 1.1 (4.3–5.2)	5.1 ± 0.7 (4.8–5.4)
Lubrication <sup>a</sup>	4.7 ± 1.0 (4.3–5.1) <sup>d</sup>	5.6 ± 0.4 (5.5–5.8)
Orgasm <sup>a</sup>	4.4 ± 1.0 (4.0–4.9) <sup>e</sup>	5.0 ± 0.6 (4.8–5.3)
Satisfaction <sup>a</sup>	5.1 ± 1.3 (4.5–5.7)	5.0 ± 1.1 (4.5–5.4)
Comfort <sup>a</sup>	4.5 ± 1.3 (4.0–5.1) <sup>f</sup>	5.6 ± 0.6 (5.3–5.8)

FSFI, Female Sexual Function Index.

<sup>a</sup> Data are given as mean ± SD (95% confidence interval); <sup>b</sup>  $P < .01$ ; <sup>c</sup>  $P < .05$ ; <sup>d</sup>  $P < .001$ ; <sup>e</sup>  $P < .05$ ; <sup>f</sup>  $P < .001$ .

Fedele. Creation of neovagina in patients with Rokitansky syndrome. *Am J Obstet Gynecol* 2010.

length and diameter of the neovagina were  $7.4 \pm 2.3$  cm and  $2 \pm 0.6$  cm, respectively. Mean follow-up examinations lasted 30 months (range, 6–44 months). Anatomic success was achieved in 97% of the operated patients ( $n = 29$ ). In 1 case, the surgery did not succeed because of the early formation of a severe fibrotic stenosis at the neovaginal introitus after 3 months from surgery. Mechanical dilation of the neovaginal introitus in this case was performed without success. The mean length of the neovagina 6 months after surgery in the other 29 patients was  $8.1 \pm 2$  cm, and the mean diameter was  $2.8 \pm 0.7$  cm.

Vaginoscopy with Schiller's test was performed in all 29 patients at 6 months and 1 year after surgery to evaluate the epithelization of the neovagina.<sup>15,16</sup> This was performed with a laparoscopic 0° optic, with an assistant retracting the neovagina using 2 small lateral retractors. The neovaginal walls appeared to be coated completely with an iodine-positive epithelium in the 29 patients with anatomic success.

Biopsies were performed of the neovaginal mucosa, which at light microscopy appeared very similar compared with the normal vagina (ie, with normal thickness, normal squamous stratification, and a glycogen-rich epithelium).

At 6 months after surgery, functional success was obtained in 23 of the 24 sexually active patients (96%). Besides the only patient who did not experience an adequate anatomic result, only 1 patient reported unsatisfactory sexual intercourse; 4 patients had not started sexual intercourse 6 months after surgery. The Table shows single domain and total scores in the 24 sexually active operated patients, compared with normal control subjects ( $n = 24$ ). The total score of the FSFI shows optimal functional results in 23 of the 24 patients. In particular, the score was very good in 8 patients (total FSFI score,  $\geq 30$ ) and good in 15 patients (total FSFI score, 24–29); only in 1 case was the total score  $< 23$ . There were no significant differences in the domains of arousal and satisfaction, although slightly lower scores with significant differences were found in the domain of lubrication, desire, orgasm, and pain for patients with Rokitansky syndrome. Seven patients experienced mild dyspareunia, which was, at times, superficial or deep.

### COMMENT

Based on our experience, the laparoscopic Davydov technique may be considered a safe and effective option for the surgical treatment of women with Roki-

tansky syndrome. The laparoscopic approach allows minimal invasiveness, an adequate visualization, optimal esthetic results, and minimal scarring in these young patients. Despite the relatively small sample size ( $n = 30$ ), Rokitansky syndrome represents a rare entity.

Adamyán et al,<sup>17</sup> in 1994, first reported a case series of 324 Davydov colpopoiesis, 27 of which were performed laparoscopically, showing the major advantages of the endoscopic approach, compared with the traditional laparotomic procedure. The mean duration of surgery in the study was 98 and 52 minutes, respectively, for the laparotomic and laparoscopic approaches. In the laparotomic and laparoscopic group, hospitalization lasted, respectively, a mean of 11 and 2 days; in the first group, 2 inadvertent enterotomies and 1 cystotomy occurred, while no complications occurred in the laparoscopic subgroup. The anatomic results that were assessed at a medium-term follow-up examination showed adequate results that were comparable in both subgroups.

Compared with the first laparoscopically assisted approach of Soong et al,<sup>10,18</sup> in our case series, the procedure was modified to a first laparoscopic step during which both mobilization and 2 purse-string sutures were obtained; a second final vaginal step included vesicorectal dissection and anastomosis of the peritoneum to the vaginal vestibulum. The Müllerian rudiments were not removed, because there have been no reports of neoplastic degeneration of the rudiments and because their excision could even temporarily affect the ovarian vascularization; their precise vascular connections with the uterine rudiments are not clear and most likely might be extremely variable. As suggested in the report by Soong et al,<sup>10</sup> to obtain a longer neovagina, peritoneal mobilization was performed prior sectioning of the round ligaments and posterolateral incisions of the peritoneal leaf along the infundibulopelvic ligaments, after which the final mean neovaginal length was increased from 6–8.5 cm after their modified procedure. Moreover, in our case series, the addition of the laparoscopic suprapubic peritoneal transverse incision facilitates

the identification of the peritoneal margin during the perineal step.

Although the duration of surgery was comparable with the case series by Soong et al,<sup>10</sup> the 2-step modification of the Davydov's laparoscopic technique can potentially shorten the procedure; the laparoscopic assistance does aid in the transvaginal identification of the peritoneal margins. Again, in a study of 28 patients, Dargent et al<sup>5</sup> reported a mean duration of surgery of 119 minutes, with a mean hospitalization of 8 days, and 4 cases of perioperative complications and 4 medium-term neovaginal stenoses. Similarly to case series of Dargent et al,<sup>5</sup> the operating times in the present study diminished after the initial cases. Although the surgical duration of this technique is longer than the laparoscopic Vecchietti procedure,<sup>19</sup> it is shorter than other procedures, such as sigmoid colpoplasty.<sup>20-22</sup> Compared with other techniques, intraoperative blood loss and vaginal bleeding after surgery are very scant. Postoperative vaginal bleeding may be intermittent during the first 2 months but is generally scant and rarely occurs. Unlike the techniques of McIndoe<sup>23</sup> and Vecchietti and sigmoid vaginoplasty, the Davydov laparoscopic technique does not require any particular surgical instrumentation and is performed by a gynecologic team alone that has to be experienced in laparoscopy and vaginal surgery.

The catheter and neovaginal gauze dressing can be removed 48 hours after surgery; therefore, the risk of bladder and neovaginal infections is minimized. Despite the mean hospitalization of 3.9 days due to 5 cases of transient urinary retention, the hospital stay is relatively short, because patients can be discharged 2–3 days after surgery (ie, after catheter removal and when the patients are capable of using the vaginal obturator).

As previously reported by Adamyan et al<sup>17</sup> and Templeman et al,<sup>24</sup> the Davydov procedure is demonstrated to allow spontaneous squamous epithelization of the neovagina within 6 postoperative months. The reason for this rapid transformation is not clear, although we might hypothesize that, despite the displaced peritoneum, it preserves its orig-

inal vascularization and thus represents an easy substrate for epithelization.

The vaginal step makes this procedure particularly indicated for patients with abnormalities of the external genitalia (such as female hypospadias) for which the creation of a neovagina by vaginal pressure (such as in the laparoscopic Vecchietti technique and Frank method) is not indicated. Patients with a pelvic kidney were excluded from our study because of the risk of damaging the kidney or ureter during the laparoscopic mobilization of the peritoneum. Similarly, previous pelvic surgery might be a relative contraindication to Davydov's technique. The presence of postoperative adhesions could complicate the surgical procedure and increase the risk of intraoperative complications (such as bleeding).

Although in the present case series there were no severe intraoperative or postoperative complications, as in all combined laparoscopic and vaginal procedures, complications of the Davydov technique may involve intraoperative damage to the bladder, ureters, or rectum, with a subsequent risk of fistula formation. A rectovaginal fistula at 18 months follow-up examination in 1 operated patient was reported in the case series of Soong et al.<sup>10</sup>

A hyatrogenic septic peritonitis could occur during the first 10 postoperative days because of the communication between the dome of the neovagina and the peritoneal cavity. Such complication probably can be prevented through sterilization of the vaginal obturator before use and cautious insertion of the obturator to avoid bringing the neovaginal discharge upward into the peritoneal cavity. Sexual intercourse should be avoided until the first postoperative month follow-up visit. No cases of peritonitis were observed in this case series.

The advantages with respect to another vaginal approach (such as the McIndoe technique) are undoubtedly the absence of major scarring from skin grafting in these frequently young patients. Despite the fact that sexuality after laparoscopic Davydov procedure is poorly documented, our results are similar to those of Giannesi et al<sup>25</sup> and Dar-

gent et al.<sup>5</sup> In our experience, the Davydov technique permitted a good functional outcome in 90% of patients who had started sexual intercourse.

The FSFI results show that, in terms of global satisfaction, there are no differences between the patients and the age-matched control group. However, compared with the case series of Soong et al,<sup>10</sup> patients with Rokitansky syndrome generally are referred more frequently for an insufficient lubrication and sometimes mild superficial or deep dyspareunia. The slight differences we have found may be due to the relatively short time spent from vaginal surgery and the early assessment of the degree of lubrication and pain, which probably should be reassessed later. Slight differences were also found in desire. There is certainly no unique interpretation of these results, although it could be due to an objective difficulty in lubrication and pain or could also be related to a subjective hyperreactivity in this particular subset of patients, with frequently late diagnoses and protracted clinical histories. Although most patients were satisfied with the surgery, it is also important to consider that success largely depends on their cooperation in maintaining the results that are obtained with the surgery.

In patients with Rokitansky syndrome, the laparoscopic Davydov technique seems to represent a safe and effective solution for the treatment of vaginal agenesis. ■

## REFERENCES

1. Willemssen WN. Renal-skeletal-ear-and facial-anomalies in combination with the Mayer-Rokitansky-Küster (MRK) syndrome. *Eur J Obstet Gynecol Reprod Biol* 1982;14:121-30.
2. Strubbe EH, Thijn CJ, Willemssen WN, Lappohn R. Evaluation of radiographic abnormalities of the hand in patients with the Mayer-Rokitansky-Kuster-Hauser syndrome. *Skeletal Radiol* 1987;16:227-31.
3. Aittomaki C, Eroila H, Kajanoja P. A population-based study of the incidence of Mullerian aplasia in Finland. *Fertil Steril* 2001;76:624-5.
4. Edmonds DK. Congenital malformations of the genital tract. *Obstet Gynecol Clin North Am* 2000;27:49-62.
5. Dargent D, Marchiolè P, Giannesi A, Benchaib M, Chevret-Mèasson M, Mathevet P. Laparoscopic Davydov or laparoscopic transposition of the peritoneal colpopoiesis described by Davydov for the treatment of con-

genital vaginal genesis: the technique and its evolution. *Gynecol Obstet Fertil* 2004;32:1023-30.

**6.** Ismail IS, Cutner AS, Creighton SM. Laparoscopic vaginoplasty: alternative techniques in vaginal reconstruction. *BJOG* 2006;113:340-3.

**7.** Davydov SN. Colpopoiesis from the peritoneum of the uterorectal space. *Akush Ginekol (Mosk)* 1969;45:60-2.

**8.** Davydov SN, Zhvitiashvili OD. Formation of vagina (colpopoiesis) from peritoneum of Douglas pouch. *Acta Chir Plast* 1974;16:35-41.

**9.** Friedberg V. [Die bildung einer Kunstlichen Scheide mittels peritoneum]. *Geburtsh Frauenheilkd* 1974;34:719-23.

**10.** Soong YK, Chang FH, Lai YM, Lee CL, Chou HH. Results of modified laparoscopically assisted neovaginoplasty in 18 patients with congenital absence of vagina. *Hum Reprod* 1996;11:200-3.

**11.** Fedele L, Bianchi S, Frontino G, Fontana E, Restelli E, Bruni V. The laparoscopic Vecchietti's modified technique in Rokitansky syndrome: anatomic, functional, and sexual long term results. *Am J Obstet Gynecol* 2008;198:377.e1-6.

**12.** Rosen R, Brown C, Heiman J, et al. The Female Sexual Function Index (FSFI): a multidimensional self-report instrument for the assess-

ment of female sexual function. *J Sex Marital Ther* 2000;26:191-208.

**13.** Fedele L, Bianchi S, Dorta M, Zanconato G, Raffaelli R. Laparoscopic creation of a neovagina in women with pelvic kidney. *J Am Assoc Gynecol Laparosc* 1999;6:327-9.

**14.** Fedele L, Frontino G, Motta F, Restelli E, Candiani M. Creation of a neovagina in Rokitansky patients with a pelvic kidney: comparison of long-term results of the modified Vecchietti and McIndoe techniques. *Fertil Steril* 2009. Epub ahead of print.

**15.** Fedele L, Bianchi S, Berlanda N, et al. Neovaginal mucosa after Vecchietti's laparoscopic operation for Rokitansky syndrome: structural and ultrastructural study. *Am J Obstet Gynecol* 2006;195:56-61.

**16.** Herman CJ, Willesman WN, Mastboom JL, Vooijs GP. Artificial vaginas: possible sources of epithelialization. *Hum Pathol* 1982;13:1100-5.

**17.** Adamyan LV, Kulakov VI, Murvatov KD, Zurabiani Z. Application of endoscopy in surgery for malformations of genitalia. *J Am Assoc Gynecol Laparosc* 1994;1:S1.

**18.** Soong YK, Chang FH, Lee CL, Lai YM. Vaginal agenesis treated by laparoscopically assisted neovaginoplasty. *Gynecol Endosc* 1994;3:217-20.

**19.** Fedele L, Bianchi S, Zanconato G, Raffaelli R. Laparoscopic creation of neovagina in pa-

tients with Rokitansky syndrome: analysis of 52 cases. *Fertil Steril* 2000;74:384-9.

**20.** Louis-Sylvestre C, Haddad B, Paniel BJ. Creation of a sigmoid neovagina: technique and results in 16 cases. *Eur J Obst Gynec Repr Biol* 1997;75:225-9.

**21.** Delga P, Potiron L. Sigmoid colpoplasty by laparoscopic and perineal surgery: a first case relative to Rokitansky-Kuster-Hauser syndrome. *J Laparoendosc Adv Surg Tech* 1997;7:195-9.

**22.** Darai E, Toullalan O, Besse O, Potiron L, Delga P. Anatomic and functional results of laparoscopic-perineal neovagina construction by sigmoid colpoplasty in women with Rokitansky's syndrome. *Hum Reprod* 2003;18:2454-9.

**23.** McIndoe AH. The treatment of congenital absence and obliterative conditions of the vagina. *Br J Plast Surg* 1950;2:254-67.

**24.** Templeman CL, Hertweck SP, Levine RL, Reich H. Use of laparoscopically mobilized peritoneum in the creation of a neovagina. *Fertil Steril* 2000;74:589-92.

**25.** Giannesi A, Marchiole P, Benchaib M, Chevret-Measson M, Mathevet P, Dargent D. Sexuality after laparoscopic Davydov in patients affected by congenital complete vaginal agenesis associated with uterine agenesis or hyoplasia. *Hum Reprod* 2005;20:2954-7.